



# Correlation Between the MRI Changes in the Lumbar Multifidus Muscles and Leg Pain

D. F. KADER, D. WARDLAW, F. W. SMITH

Departments of Radiology and Orthopaedic Surgery, Woodend Hospital, Eday Road, Aberdeen, AB15 6XS, U.K.

Received: 5 January 1999 Revised: 13 July 1999 Accepted: 19 July 1999

**AIM:** In the assessment of the lumbar spine by magnetic resonance imaging (MRI), changes in the paraspinal muscles are frequently overlooked. In this study, our objective was to investigate the relationships between lumbar multifidus (MF) muscle atrophy and low back pain (LBP), leg pain and intervertebral disc degeneration.

**METHODS:** A retrospective study of 78 patients (aged 17–72) with LBP presenting with back pain with or without associated leg pain was undertaken. Their MR images were visually analysed for signs of lumbar MF muscle atrophy, disc degeneration and nerve root compression. The clinical history in each case was obtained from their case notes and pain drawing charts.

**RESULTS:** MF muscle atrophy was present in 80% of the patients with LBP. The correlation between MF muscle atrophy and leg pain was found to be significant ( $P < 0.01$ ). However, the relationships between muscle atrophy and radiculopathy symptoms, nerve root compression, herniated nucleus pulposus and number of degenerated discs were statistically not significant.

**CONCLUSION:** Examination of the paraspinal muscles looking for atrophy of MF muscle should be considered when assessing MR images of lumbar spine. This may explain the referred leg pain in the absence of other MR abnormalities. Kader, D. F. *et al.* (2000). *Clinical Radiology* 55, 145–149.

© 2000 The Royal College of Radiologists

**Key words:** magnetic resonance imaging, MRI, multifidus muscle, paraspinal muscle.

Low back pain (LBP) is a major health problem. It is regarded as the second most common presenting complaint to all physicians, following only upper respiratory illness [1]. Eighty per cent of the adult population suffer at least one episode of LBP during their lifetime [2]. Despite this, the pathophysiology of LBP is poorly understood and there is inadequate correlation between investigative findings and clinical symptoms. The role of the paraspinal muscles in the causation of LBP and sciatica remains unclear. There are indications that the multifidus (MF) muscle is sensitive to different pathologic changes in the lumbar spine, e.g. radiculopathy, disc and facet degeneration [3–5]. However, it is not known whether paraspinal muscle atrophy is a cause or a result of different pathological processes in the lumbar spine. Knuts-son [3] showed a 60% incidence of abnormal paraspinal muscles in surgically proven herniated discs. Hides *et al.* [6] demonstrated reduction in cross-sectional area of MF muscle on the ipsilateral side in patients with unilateral LBP. A recent electromyographic study on porcine MF muscle has shown that stimulation of the intervertebral disc or facet joint capsule will produce contraction in MF muscle, suggesting that there may

be interactive responses between diseased structures [5]. Histopathologic analysis of MF muscle biopsy in patients with disc herniation revealed abnormalities described as core-targetoid and/or moth-eaten changes in the paraspinal muscles attributed to denervation, ischaemia, or altered use of the back muscles due to pain [7].

To date, the paraspinal muscles, especially the MF muscle have been subjected to many studies by ultrasound, needle EMG and histopathological analysis. The development of MRI may provide a unique insight into our understanding of the paraspinal muscle pathology in relationship to LBP and leg pain.

In this study our objective was to define what is the significance of lumbar muscle wasting as observed in MRI images and to evaluate the effect of LBP, leg pain, disc degeneration and nerve root compression on the lumbar multifidus muscles.

## Multifidus Muscle

The multifidus muscle is the largest and most medial of the lumbar paraspinal muscles. Its anatomy and function has only recently been defined precisely by Bogduk and Twomey [8]. Morphologically there is some similarity between the muscle and a conifer tree (Fig. 1). It consists of five separate bands,

Author for correspondence and guarantor of study: Dr F. W. Smith, M.R.I. Centre, Department of Radiology, Woodend Hospital, Eday Road, Aberdeen AB15 6XS, Scotland, U.K.

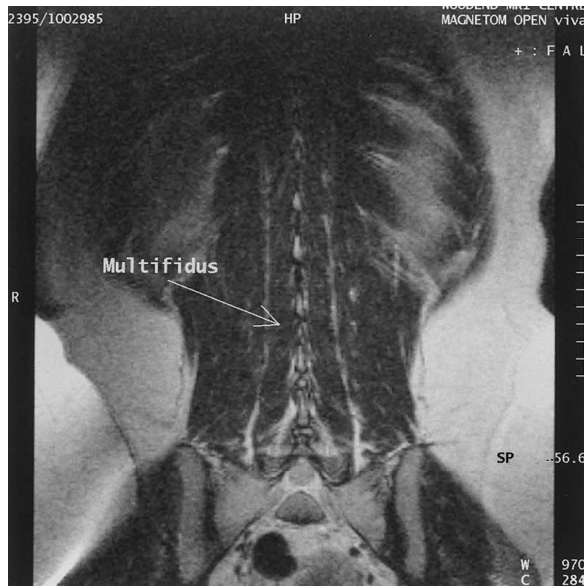


Fig. 1 – T2 weighted coronal image showing multifidus muscle.

each originating from a spinous process and spreading caudolaterally from the midline to be inserted into the mamillary processes of the facet joints, the iliac crest and the sacrum [8,9]. They are innervated unisegmentally by the medial branch of the dorsal ramus. When the MF muscle is displayed in an axial MR image we therefore see two, three or four bands depending on the level of the image. The MF muscle maintains the lumbar lordosis by acting like a bowstring which helps in transmitting some of the axial compression force to the anterior longitudinal ligament, also it protects the discs by preventing unwanted movements like torsion and flexion.

## METHOD

Ninety patients were studied. All had mechanical low back pain or lower back pain with leg pain (radicular or non-radicular) of more than 3 months duration before referral for MRI of the lumbar spine. Patients with spinal fracture, tumour, infection, structural deformity or previous surgery were excluded from the study. The MR examinations were performed between May 1997 and August 1997. Seventy-eight patients (40 women and 38 men; age range, 17–72; mean, 46 years) were unsuitable for the study. Twelve patients were excluded; five had had previous surgery, three had spinal deformity with asymmetry in the muscle sections, in three cases the history was inadequate and one scan was of poor quality.

The lumbar spine MR images of the 75 patients were visually analysed by three independent observers blinded to the clinical history. The side and level of MF muscle degeneration in axial and sagittal views were identified by a decrease in the muscle size and deposition of fat and connective tissue, which shows as high signal intensity on the fast spin echo (FSE) T2 weighted images used. We also assessed the longitudinal extent of MF muscle atrophy.

Atrophy of the muscle was graded as mild, moderate and

severe. Mild muscle atrophy is defined as replacement of less than 10% of the MF muscle bulk with fat and fibrous tissues (Fig. 2*b*). Moderate muscle atrophy is the replacement of less than 50% of the MF muscle with fat and fibrous tissues (Fig. 2*c*). Severe atrophy is replacement of more than 50% of the MF muscle with fat and fibrous tissues associated with atrophy of other paraspinal muscles (Fig. 2*d*). Although we graded the MF muscle atrophy during the evaluation, we only registered moderate and severe MF atrophy as present and regarded mild changes of less than 10% of the muscle bulk in the superomedial part of the MF muscle as variation of normal [14]. In addition, the axial and sagittal views were assessed for signs of spinal stenosis, disc degeneration and nerve root compression.

The clinical details were collected from the case notes and pain drawing charts. The latter are regarded as a very reliable method of ascertaining the character and distribution of pain as perceived by the patient. Sharp, burning or stabbing pain, which localized to a dermatomal distribution mainly below knee, was regarded as root pain, while diffuse dull aching pain above or below knee was regarded as referred pain. The intensity of pain was determined as mild, moderate or severe.

## IMAGING PROTOCOL

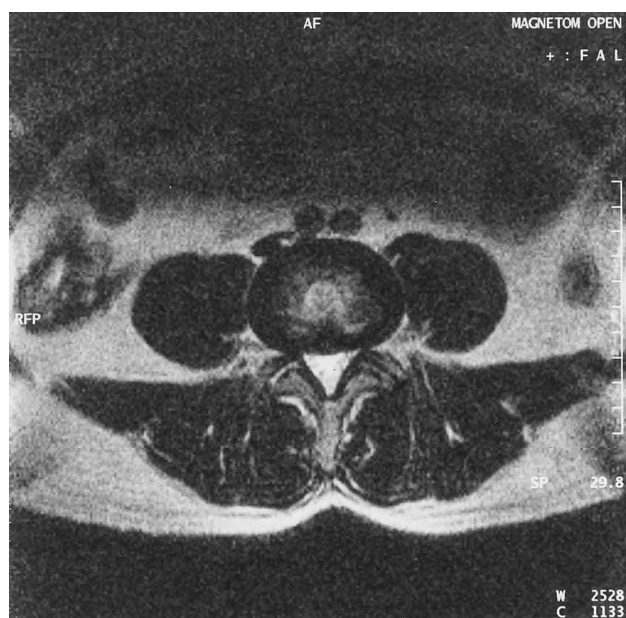
The magnetic resonance images were obtained using a 0.2 Tesla resistive Open imaging system (Magnetom Open Viva, Siemens, Erlangen, Germany). A dedicated spinal coil was used for transmission and reception. The MR protocol included two fast spin echo sequences with different T2 weighting. Images were obtained in the sagittal and axial planes. In both the sagittal and axial planes the following parameters were used; TR 4000/TE 134 with an echo train of 15, section thickness 5 mm, FOV 350 mm, two signals were averaged. In the axial plane, a TR 3000/TE 106 with an echo train of 5, section thickness 5 mm, 250 mm FOV was used, averaging four signals.

## STATISTICS

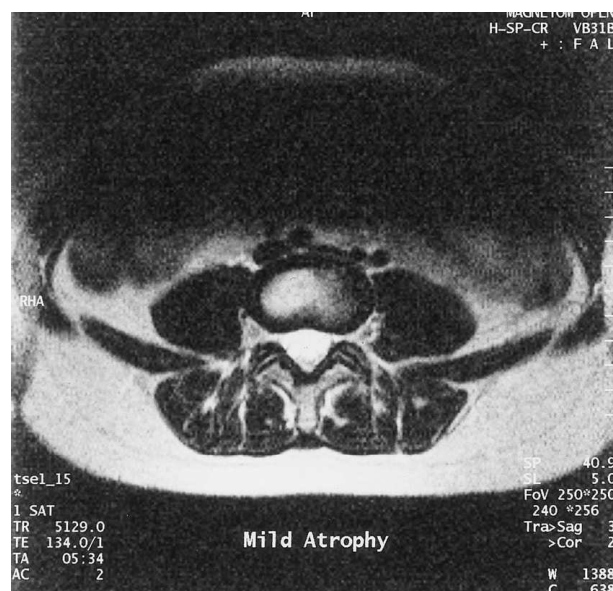
The SPSS software was used for statistical analyses. The relationship between MF muscle atrophy and LBP, leg pain and nerve root compression were estimated using Pearson's chi-squared test. Fisher's exact test was also used in cases when the expected values were small. The number of degenerate discs distributed between the normal and abnormal MF muscle groups were compared using the Mann–Whitney *U*-test. The interobserver agreement in assessing muscle degeneration, disc degeneration and nerve root compression was tested using the Kappa coefficient.

## RESULTS

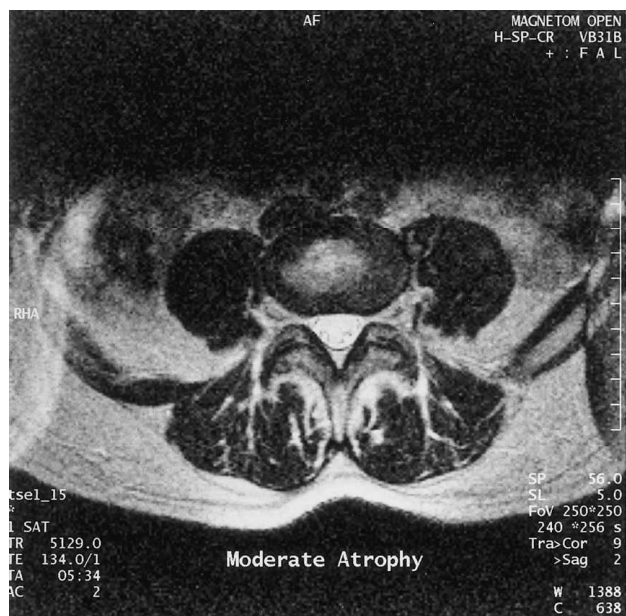
Macroscopic degeneration in MF muscle was present in 80% of the patients with LBP in the axial MR views. In the majority of the cases it was bilateral (Table 1) and demonstrated mainly



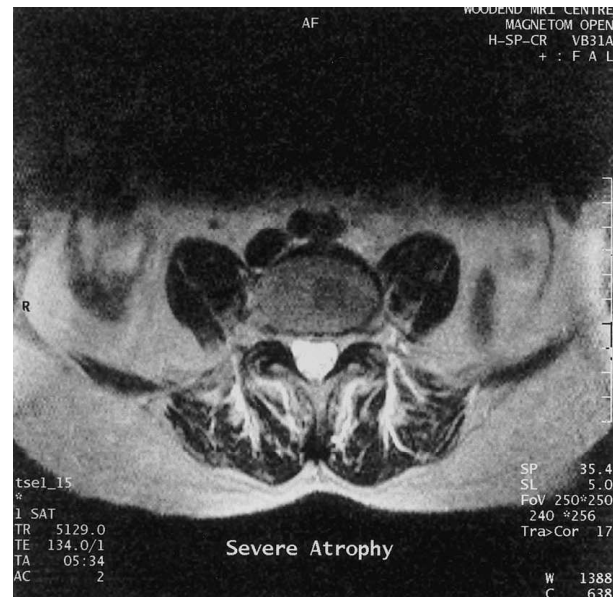
(a)



(b)



(c)



(d)

Fig. 2 – T2 axial images, gradient echo TR/TE 3000/106 sequence with an echo train of 5, slice thickness 5 mm, showing lumbar paraspinal muscles. (a) Normal multifidus and erector spinae muscles. (b) Mild multifidus degeneration. (c) Moderate multifidus degeneration. (d) Severe multifidus and erector spinae muscles degeneration.

at both the L4/5 and L5/S1 levels together (Table 2). Muscle atrophy was more common among the older age group and female patients. Interobserver agreement was good. For estimation of muscle degeneration, Kappa value = 0.85, and for nerve compression, Kappa value = 0.70, while the Kappa estimate for disc degeneration varied from 0.74–0.88 at different levels. 66/78 (85%) of the patients had disc degeneration, most commonly affecting the L4/5 level, followed by the L5/S1 discs (Table 3). Sixty-six of the 78 patients had degenerated

discs; the number of degenerate discs was found to be higher in the older age group (46–72 years).

The most important finding was the significant correlation between lumbar MF muscle atrophy and leg pain (radicular and non-radicular) ( $P < 0.01$ ). Nevertheless, the relationships between muscle atrophy and radiculopathy symptoms ( $P = 0.08$ ), nerve root compression ( $P = 0.14$ ), herniated nucleus pulposus ( $P = 0.1$ ) and number of degenerated discs ( $P = 0.08$ ) were statistically not significant. Furthermore, the correlation between

**Table 1 – Multifidus muscle atrophy sides in the MRI and leg pain side**

Affected sides	Number of patients with muscle atrophy in the axial MR images	Number of patients with leg pain as shown in the pain drawing charts
Bilateral	56	15
Left	4	23
Right	3	19
Total	63	57

intensity of pain and the severity of muscle atrophy was statistically not significant but there was a trend in the relationship demonstrating the possible increase in muscle atrophy with high pain score.

It is noteworthy that 18 of the 38 patients with root pain and 25 of the 57 patients with leg pain (radicular and non-radicular) only had MF muscle atrophy without any other MRI abnormalities such as herniated nucleus pulposus, spinal stenosis or nerve root compression.

### DISCUSSION

This study demonstrates that atrophy of the MF muscle is common and easy to diagnose in both sagittal and axial T2 views of MR images, with good interobserver agreement. However, all of the observers agreed that the MF muscle atrophy was clearer in the axial views. Muscle degeneration was usually bilateral and multilevel even in patients with single nerve root irritation. It was difficult to visualize each band of the muscle and localize it segmentally in all standard axial views, despite efforts made to choose the most appropriate section. Therefore, we were unable to comment on the possibility of unisegmental, i.e. single band, involvement of the MF muscle as a result of radiculopathy. We think that adding T2 coronal views to the imaging protocol may help to identify MF muscle fascicle atrophy in relationship to other abnormalities of the lumbar spine.

In previous study, by Parkkola *et al.* [14], the average amount of fat within the back muscles was 9% in healthy middle-aged volunteers. Therefore, when we graded the multifidus muscle atrophy we regarded less than 10% loss in muscle bulk as variation of normal [13].

It is widely accepted that LBP which radiates above the knee is referred while that radiating below the knee radiation is mainly root pain. However, many studies have shown that referred pain generated by stimulation of facet joints, interspinous ligament, lumbar MF or dorsal ramus nerve can travel a long distance down the leg [9–12], and in certain cases may

follow a segmental pattern [10], or be associated with sensory abnormality [13] which may be confused for root pain. Kellgren in 1938 [10], showed that stimulation of the MF muscle opposite the fifth lumbar spine produced pain in the lateral aspect of the thigh and the leg, indicating that pain arising from muscle may be referred to the leg. Similarly, Bogduk [9] proved that electrical stimulation of the medial branch of L5 dorsal rami evoked pain referred in the thigh, shin and foot [9].

The wasting in the MF muscle may be caused by the Lumbar Dorsal Ramus Syndrome, which is defined as LBP with referred leg pain induced by irritation to structures innervated by the dorsal ramus nerve, e.g. facet joints, MF muscle and interspinous ligaments, or by myofascial injury due to acute or chronic trauma which initiates myofascial pain, spasm and ischaemia [11]. This triggers a self-sustained vicious cycle that promotes muscle atrophy. Bonica in 1957 stated that myofascial pain in the MF muscle could cause LBP and pain referred to the thigh [11].

MR images of the lumbar spines of healthy individuals may show paraspinal muscle degeneration, but significantly less than patients with LBP [14]. Therefore, it is of paramount importance that the muscle atrophy is considered in association with the clinical presentation and other abnormalities seen in the MRI examination.

It is not our intention in this study to define the exact cause of MF muscle atrophy but to draw the attention of radiologists and back clinicians to the significance of MF muscle atrophy seen in MRI. We propose that it may help explain the referred leg pain in the absence of other MRI abnormalities. Furthermore, it may be of help in diagnosing Lumbar Dorsal Ramus Syndrome and myofascial pain which can then be treated with specific physical therapy and injection of local anaesthetic with steroids.

We conclude that atrophy of MF muscle should be considered when assessing MR images of lumbar spine. This may provide extra information, which helps towards the diagnosis of leg pain. Further study will be required to assess MRI changes of paraspinal muscles in response to specific exercise with local anaesthetic and steroid injections.

**Table 2 – Extent of MF muscle atrophy in the axial views**

Affected levels	Number of patients
L3/S1 3 levels	7
L4/5 1 level	5
L4/S1 2 levels	33
L5/S1 1 level	18

**Table 3 – The prevalence of disc degeneration in the 78 patients**

Number of degenerate discs	Patients affected
1	14
2	22
3	10
4	10
5	10

**Acknowledgements.** The authors thank Heather Atchison and Beverley Leitch (MRI Centre, Woodend Hospital) for their technical support and Janet Square (Department of Public Health, University of Aberdeen) for statistical advice.

### REFERENCES

- 1 Cypress BK. Characteristics of physician visits for back symptoms: a national perspective. *Am J Public Health* 1983;73:389–395.
- 2 Chakera TMH, McCormick CC. Radiology and low back pain. *Australian Family Physician* 1995;24:24.
- 3 Knutsson B. Comparative value of electromyographic, myelography, and clinical neurological examination in the diagnosis of lumbar root compression syndrome. *Acta Orthop (Scand)* 1961;49:71–100.
- 4 Johnson EW, Melvin J. Value of electromyography in lumbar radiculopathy. *Arch Phys Med Rehabil* 1971;52:239–243.
- 5 Indahl A, Kaigle A, Reikeras O, Holm S. Electromyographic response of the porcine multifidus musculature after nerve stimulation. *Spine* 1995;20:2652–2658.
- 6 Hides JA, Stokes MJ, Saide M, Jull GA, Cooper DH. Evidence of lumbar multifidus muscle wasting ipsilateral to symptoms in patients with acute/subacute low back pain. *Spine* 1994;19:165–172.
- 7 Mattila M, Hurme M, Alaranta H, *et al.* The multifidus muscle in patients with lumbar disc herniation. *Spine* 1986;11:732–738.
- 8 Bogduk N, Twomey LT. *Clinical Anatomy of the Lumbar Spine*. Melbourne PA: Churchill Livingstone; 2nd edn; 1991;86–89.
- 9 Bogduk N. Lumbar Dorsal Ramus Syndrome. *Med J Aust* 1989;15:537–541.
- 10 Kellgren JH. Observations on referred pain arising from muscle. *Clin Sci* 1938;3:175–190.
- 11 Bonica JJ. Management of myofascial pain in general practice. *JAMA* 1957;164:732–738.
- 12 Steindler A, Luck JV. Differential diagnosis of pain low in the back. *JAMA* 1938;8:106–112.
- 13 Sinclair DC, Feidel WH, Weddell G, Murray A, Falconer. The intervertebral ligaments as a source of segmental pain. *J Bone Joint Surg* 1948;30B:515–521.
- 14 Parkkola R, Rytokoski U, Karmano M. Magnetic resonance imaging of the discs and trunk muscles in patients with chronic low back pain and healthy control subjects. *Spine* 1993;18:830–836.